Long term provisionalization during periodontal surgery and extraction site tissue grafting: A Case Review

Michael Tischler, DDS
Diplomate American Board Of Oral Implantology/Implant Dentistry

(Images are at the end of article)

Abstract:
Extraction of anterior teeth and provisionalization of the remaining dentition during periodontal surgery presents an esthetic and functional challenge. Utilization of a laboratory-processed provisional that supports papillae, stabilizes remaining teeth, offers ideal esthetics during the surgical phase of treatment, and can offer many benefits to the patient and dentist. A full mouth reconstruction case is presented utilizing Biotemps ™ laboratory processed provisionals. The steps taken and clinical photographs of the case are presented.

Introduction:
When presented with the challenge of full mouth reconstruction that involves periodontal surgery, extractions and tissue grafting, provisionalization becomes an important focus of the treatment plan. A laboratory processed fixed provisional can offer periodontal splinting of remaining teeth, ideal esthetics, papillae formation via ovate pontics, and reduced breakage of the provisional during the treatment period. [1] Further benefits of a laboratory-processed provisional include less chair time, a higher polish, and metal reinforcement that an in-office delivered fixed provisional does not offer.[2] A full mouth periodontal surgery and extraction reconstruction case is presented that utilizes Biotemps ™ laboratory processed provisionals. The clinical steps taken and benefits of these provisionals are presented.

Treatment plan:
A 43 year old male patient presented with a desire to improve the esthetics and health of his mouth. Examination revealed advanced periodontal disease with overall periodontal pocketing ranging from 5-7mm. (fig1) The anterior teeth had extensive bone loss and were angled in an unaesthetic protrusive direction. (fig 2) Tooth mobility ranged from class 2 in the maxillary anterior to class 1 in the maxillary posterior. The mandibular teeth exhibited less advanced periodontal disease and mobility as compared to the maxillary arch.

The final treatment plan consisted of 1) extraction of teeth numbers 7,8,9,10 with grafting of the extraction sites using Demineralized Freeze Dried Bone Allograft Putty DFDBA, 2) full arch splinting of the remaining maxillary and mandibular teeth with laboratory processed provisionals that incorporate ovate pontics into the anterior extraction sites 3) periodontal surgery of the remaining maxillary and mandibular teeth 4) permanent porcelain fused to metal restorations after successful healing of the periodontal surgery and grafting. The final treatment plan was determined after the options of tooth replacement with dental implants and removable partial dentures were discussed with the patient.

Treatment Sequence:

After the treatment plan was determined and informed consent was given to the patient, study models were taken of the patient's maxillary and mandibular arch. The study models and a bite registration were sent for the fabrication of the laboratory fabricated provisional fixed prosthesis. An integral part of the treatment plan was an assessment of the bone height and tissue form of the anterior region. Through a thorough assessment the predictability of the final esthetic outcome can be better ascertained. [3] The previous work published by Garber and Rosenberg help create a framework for improved success with respect to an edentulous area. [4] The instructions on the lab slip were to create a full arch prosthesis for the maxillary and mandibular arch. Special instruction was given to create ovate pontics in the areas of 7,8,9,10 for papillae support after tooth extraction.[5] Utilization of smooth surfaced ovate pontics supports the adjacent papillae, and allows for ideal esthetic papillae formation during bone grafting after extraction. The author also routinely asks for the fabrication of a vacuform stent of the temporary prosthesis when doing full arch reconstruction cases. The stent is used to record vertical dimension and bite registration through relining the stent with a medium body addition silicone. This is used when the final impressions are sent to the lab.

After a ten day period, the provisional prosthesis were returned from the lab, and the patient presented for treatment. (Fig 3, Fig 4) After adequate infiltration of Lidocaine 2% 1/100,000 epinephrine, the maxillary teeth were prepared for the provisional restorations. The laboratory prepares the model so that minimal reduction of tooth structure is needed for the laboratory-processed temps to fit. The mobile teeth numbers 7,8,9,10 were extracted via forcep rotation in an atramatic manner. Atramatic extraction is important so that the remaining walls of bone are left intact for graft containment, papillae support, and adequate blood supply to the graft. [6] The Biotemps ™ provisional was then tried in to see if there was adequate tooth reduction. Once the provisionals were seated, they were then relined with a poly methyl methacrylate. Excess acrylic was then removed. The extraction sites were then curetted and Demineralized Freeze Dried Bone Allograft Putty (Grafton- Osteotech, Inc Eatontown, NJ) was placed into the extraction sockets.[7] The advantages of DFDBA Putty are ease of handling, hemostasis, osteoinduction, lack of migration from site, and a lack of resistance from the ovate pontic shape. (Fig 5)

Figure 6 shows the compressed DFDBA into the extraction sites and the hemostasis achieved. The provisionals were then placed onto the prepared teeth to compress the grafted area with the ovate pontic. Through grafting of bone, the relationship between the contact points and the crest of the ridge could be enhanced. Through obtaining a 5mm or less relationship between the contact point and the crest of bone, inter dental papillae formation is enhanced. [8] A membrane was not utilized since the ovate provisionals offered protection of the graft material and lack of mobility to the site. Note how the papillae are supported with the ovate pontics. (Fig 7) The ovate pontics were placed 2.5mm into the site and were then shortened to 1.5 mm 4 weeks later as advocated by Spear. [9] The wire reinforced provisionals offers cross arch stabilization as can be seen on the panograph (Fig 8)

The identical tooth preparation and relining procedure was followed for the mandibular arch. The patient was observed in 3 weeks at the start of the periodontal surgery. (Fig 9) Following periodontal surgery the patient was observed after a 2 month healing period with the provisionals in place. (Fig 10) 2-3 mm pocketing was noted throughout the patients mouth without any bleeding upon probing. Upon removal of the provisionals, there was minimal mobility noted on the remaining teeth. At 5 months post grafting, the tissue formed by the ovate pontics was formed and ready for a final impression. (Fig 11)

At 6 months re-preparation of the remaining teeth was done, and final impressions were made of the maxillary and mandibular arch utilizing poly ether. The final prosthesis shows improved esthetics and a healthy dental alveolar relationship. (Fig12, Fig 13) The patient was comfortable and extremely pleased with his dramatically different new image.

Conclusion:

A full mouth reconstruction case was presented that utilized Biotemps ™ laboratory processed provisional fixed prosthetics. The advantages of utilizing the Biotemps ™ provisionals include ideal esthetics, improved stability, ideal ovate pontic form, and predictability for cases that involve a long provisionalization time. Through utilization of this type of provisional, the author has found increased case acceptance, and favorable feedback from his patients. The sequences and rationalization of materials were presented including the grafting material and importance of ovate pontic shape. Through utilization of these techniques, treatment is simplified and results are enhanced.

1. Schweikert E. Successful full-mouth reconstruction with laboratory-fabricated provisionals.
Dent Today 1995 Apr;14(4):80, 82, 84-5

2. Rankin L. Provisionals: not just temporaries Trends Tech Contemp Dent Lab 1996 Jan-Feb;13(1):32-6

3. Kois JC, Predictable single tooth peri-implant esthetics: five diagnostic keys. Compend Contin Educ Dent. 2001 Mar;22(3):199-206; quiz 208.

4. Garber DA Rosenberg ES, The edentulous ridge in fixed prosthodontics. Compend Contin Educ Dent. 1981 Jul-Aug;2(4):212-23.

5. Miller MB. Ovate pontics: the natural tooth replacement.
Pract Periodontics Aesthet Dent Mar;8(2):1401996

6. Tischler M. Grafting the anterior maxilla after tooth loss from external resorption. A case report. Dent Today 2002 Apr;21(4):90-3

7. Schwartz Z, Mellonig JT, Carnes DL, et al. Ability Of Commercial Demineralized Freeze-Dried Bone Allograft To Induce New Bone Formation. *J Perio.* 1996 ; 67: 918-926

8. Tarnow DP, Magner AW, Fletcher P. The effect of distance from contact point to the crest of bone on the presence or absence of the interproximal dental papilla. J Periodontol 1992;63(12):995-996

9. Spear FM, Maintenance of the interdental papilla following anterior tooth removal. Pract Periodontics Aesthet Dent. 1999 Jan-Feb;11(1):21-8; quiz 30.

Figure Legend:

Fig 1. Patients panograph before treatment.

Fig 2 Patients pre operative clinical condition

Fig 3 View of Biotemps full arch provisional prosthesis. Note ovate pontics.

Fig 4 Facial view of maxillary provisional restoration.

Fig 5 Extraction sites with placement of Grafton Matrix Plug.

Fig 6 Extraction sites after placement of Grafton Matrix Plug. Note hemostatsis.

Fig 7 Trying in of provisional prosthesis.

Fig 8 Panograph of provisional restorations

Fig 9 Seating of provisional prosthesis. Note papillae support offered.

Fig 10 Provisional prosthesis at 3 weeks post extractions.

Fig 11 Form of tissue from ovate pontic formation

Fig 12 Final porcelain fused to metal prosthesis

Fig 13 Final treatment panograph

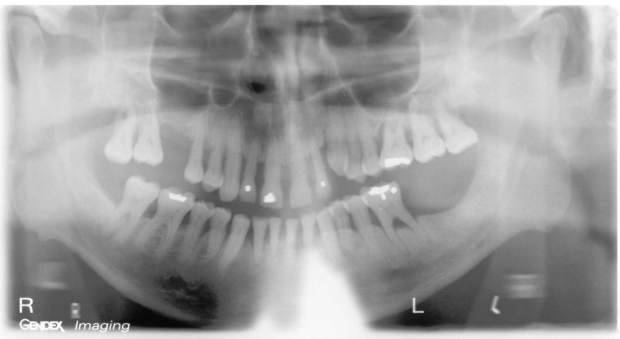

Fig 1

Fig 2

Fig 3

Fig 4

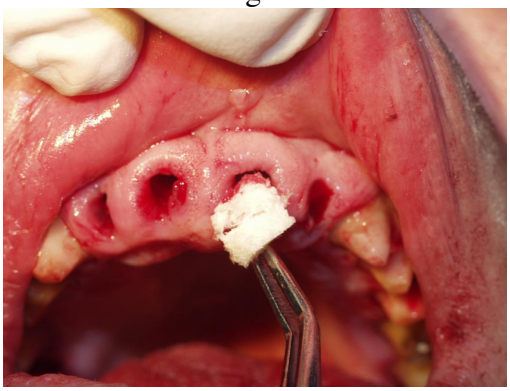

Fig 5

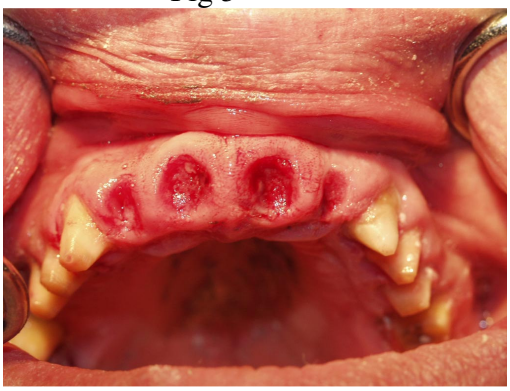

Fig 6

Fig 7

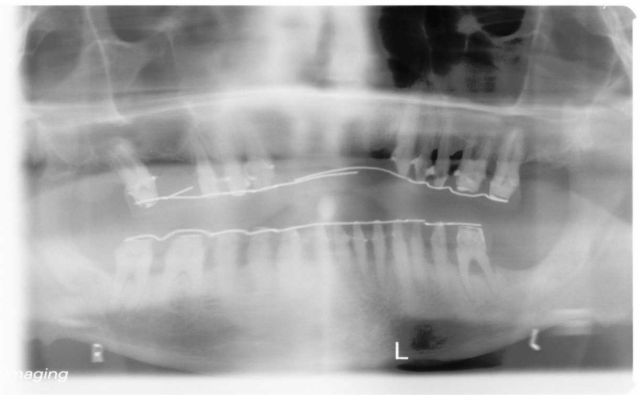

Fig 8

Fig 9

Fig10

Fig 11

Fig 12

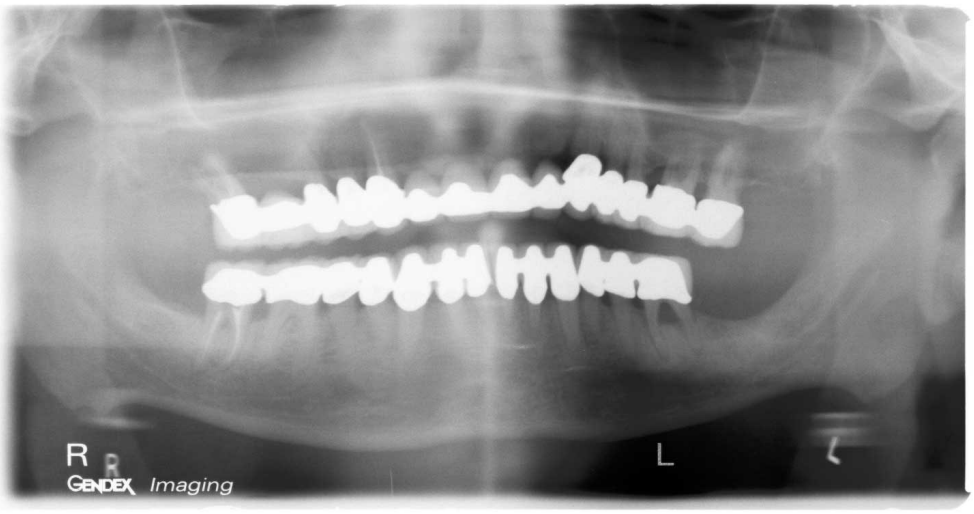

Fig 13